

A Vision for the Future: Pathology and Emerging Treatments of Age-Related Macular Degeneration

Laura Gleeson

Third Year Medicine, TCD

Clinical Points:

- Two forms of age-related macular degeneration (AMD) exist, a non-exudative form and an exudative form.
- Non-exudative AMD usually presents as slight blurring of central vision and mild metamorphopsia. A central scotoma may develop and progress over years.
- Current management of non-exudative AMD involves little more than advice on risk factor management, however the scene is set for dramatic changes, with Canada pioneering groundbreaking new treatment.
- Exudative AMD typically involves an abrupt onset of blurred central vision, relative or absolute central scotoma, and metamorphopsia. Symptoms can deteriorate within days or over months.
- Treatment of exudative AMD has developed rapidly in recent times, and new anti-angiogenic therapies are being increasingly used worldwide.

ABSTRACT

Age-related macular degeneration impacts vastly on elderly populations, particularly in the developed world. The less severe, non-exudative form of the disease is characterised by hypopigmentation of the retina due to atrophic changes in the retinal pigment epithelium. The exudative form is caused by the formation of choroidal neovascular membranes subretinally. Trials of new treatments for the non-exudative form are currently underway and rheopheresis therapy is now available in both Canada and Germany. Treatment of the more severe exudative form has been revolutionised in the past ten years with the advent of transpupillary therapy, intravitreal steroid injections and photodynamic therapy. Most significant is the emergence of anti-angiogenic drugs pegaptanib, ranibizumab and bevacizumab. The future is hopeful, with research ongoing into genetic factors, immunotherapy and new surgical techniques also.

INTRODUCTION

Age-related macular degeneration (AMD) is the leading cause of irreversible blindness in the western world. Of the population over 75 years of age, 3.5% suffer visual impairment due to the disease and this figure is rising (1). In Ireland a 113% increase was seen in the number on the Blind Register due to this condition from 1996 to 2003 (2). While 90% of AMD is classified as non-exudative “dry” AMD, the less common exudative “wet” AMD is more severe. The condition carries with it severe implications for a patient’s quality of life (1). Management of AMD has never achieved much success, and a diagnosis of exudative AMD has virtually been a promise of progression to blindness (3). However, this convention has been obliterated in the past ten years as the world witnessed the birth of a new era for AMD treatment. A myriad of groundbreaking approaches in terms of therapy are being contemplated with an enthusiasm and vigour the condition has never excited before. The purpose of this paper is to broadly explain the pathogenesis of AMD and to provide an understanding of the revolution of its treatment that has occurred in the past decade.

Non-exudative vs Exudative AMD

According to the international classification and grading system for AMD, the condition cannot be diagnosed in individuals younger than fifty years. Non-exudative AMD, also called geographic atrophy, is characterised by the appearance of hypopigmentation of the retina, often juxtafoveally. This form of the disease is relatively slow in

its progression, with the development of blindness taking several years after the disease has been identified in both eyes. In contrast, exudative AMD, also known as neovascular AMD, follows a much more rapid course and is therefore acknowledged as being the more severe of the two. It is recognised by the appearance of choroidal neovascular (CNV) membranes and the accumulation of subretinal haemorrhages and scarring which can progress within days or months. Blindness usually occurs in a matter of months if both eyes are affected by exudative AMD.

PATHOLOGY

The pathology of AMD centres on age-related changes in Ruysch’s complex located at the outer retina (the retinal layer adjacent to the choroid layer) (4). Ruysch’s complex comprises the retinal pigment epithelium (RPE), Bruch’s membrane and the choriocapillaries (see Fig.1.).

RPE and Dry AMD

The RPE carries out several important functions, most notably regeneration of rhodopsin (the photoreceptor pigment) and phagocytosis of old photoreceptor components. The accumulation of lipofuscin (a “wear and tear”/ “aging” pigment) in the RPE cells compromise this phagocytic function (5). In addition, lipofuscin contains the compound A2E (a by-product of rhodopsin recycling). A2E inhibits the lysosomal proton pump resulting in leakage of lysosomal contents which ultimately leads to cell death. The resulting decrease in the RPE cell population increases the workload of the remaining RPE cells, further

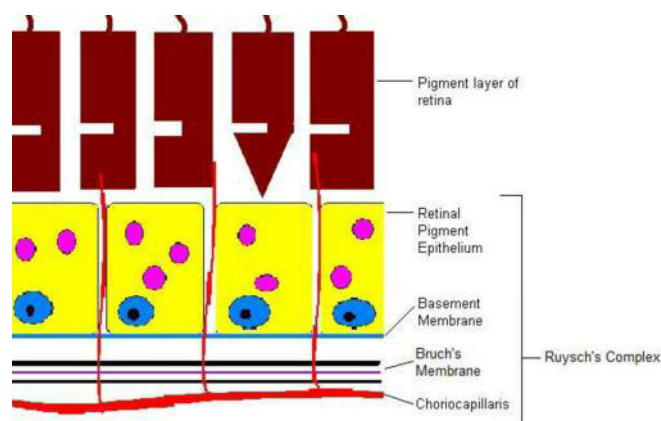


Fig. 1. Illustration of the outer layer of the retina and Ruysch's complex. Lipofuscin accumulates in the lysosomes of the RPE cells with increasing age. The potential space between the RPE Basement Membrane and Bruch's Membrane is the site of drusen accumulation in dry AMD and the site of CNV formation in wet AMD.

compromising their function. This is particularly prominent in the para-foveal regions involved in dry AMD (6). The death of RPE cells results in loss of lipofuscin, giving rise to the areas of hypopigmentation characteristic of dry AMD.

Bruch's Membrane and Dry AMD

Bruch's membrane, secreted by and lying external to the RPE, is made up of two collagenous layers enclosing a central elastic layer. The potential space between the basement membrane of the RPE and Bruch's membrane is the site of accumulation of drusen (7). The pathogenesis of this accumulation is not understood but it is noted that the substance, made up of a glycoprotein core, RPE debris, and other proteins, including inflammatory proteins (8), induces a chronic inflammation in the area causing further damage to tissue.

Hypoxic Changes and Wet AMD

Exudative or neovascular AMD is thought to result from hypoxic changes in the retina (4). Hypoxia ensues when the blood supply of the retina, coming entirely from the choriocapillaris, is compromised due to a combination of decreasing lumen diameter of the vessels and decreasing permeability of Bruch's membrane (due to rising lipid content and membrane thickening) as happens with advancing age (9). Hypoxia induces production of various growth factors in the retina. Of note is the production of Vascular Endothelial Growth Factor (VEGF) on the external side of the RPE, adjacent to Bruch's membrane (10). VEGF, which promotes angiogenesis, is thought to be responsible for the invasion of this plane by new vessels branching from the choriocapillaris, forming the choroidal neovascular (CNV) membrane (11). The new subretinal vessels tend to grow in centripetal fashion toward the fovea. As the thickness of the elastic layer of Bruch's membrane in the fovea is approximately one third that in the peripheral retina, it is hypothesised that this growth pattern may simply be following the path of least tissue resistance (4). CNV membrane development leads to exudation, bleeding and scarring (12). The accumulation of serous or haemorrhagic fluid can then cause the RPE to detach from Bruch's membrane, accounting for the rapid

deterioration in visual acuity seen with the exudative form of the disease (4).

TREATMENT

Ten years has seen major advances in the treatment of AMD. Exudative AMD, as the more severe form of the disease, has received the most attention, with exciting new therapies showing great promise for the future. Since 2003, however, dry AMD has become the focus of some interesting trials using novel approaches.

Treatment of Non-Exudative AMD

Current treatments for non-exudative or dry AMD are scarce. Essentially, little can be done beyond risk factor control (1). Patients are advised to stop smoking, to keep blood pressure under control and to eat a diet high in carotenoids (a retinal pigment component), high in antioxidants and low in fat. A randomised controlled trial currently underway is suggesting that substantial benefits can be derived from dietary supplementation with the antioxidant lutein also (13,14). Other trials are investigating a number of novel treatments for dry AMD (15). Rheopheresis, a technique used to filter larger proteins from the circulating blood, is proposed to reduce progression of dry AMD by enhancing the microcirculation of the choriocapillaries (16). This treatment option for dry AMD is currently approved in Canada, a decision justified by interim reports from a double-blind, randomised, multi-centre clinical trial (The Multicenter Investigation of Rheopheresis for AMD) (17). The success of a number of trials currently underway is likely to determine whether rheopheresis will be approved by both the FDA and the European Commission (15). Oral fenretinide decreases serum retinol (a compound present in rhodopsin). This decreases the production of A2E (the toxic lipofuscin component that is a by-product of rhodopsin recycling) and slows the process of geographical atrophy. Results of a Phase II trial investigating this novel approach to treatment are expected in 2009 (18).

Treatment of Exudative AMD

Conventional treatments for the more severe exudative form or wet AMD are limited at best (19). Irradiation of the CNV membrane with argon laser, for example, first reported in the 1980s, leaves the patient with significant damage to the overlying retina (20). Removal of CNV membranes using subretinal surgery did not benefit the vast majority of patients, despite some success stories (21). Over the past ten years, however, sophisticated treatments have been developed to treat this disease (4).

Transpupillary thermotherapy (TTT), a process which targets the CNV membrane vessels with infrared diode laser energy to occlude the vessels (with the infrared wavelength used minimising thermal injury to the overlying retina), was found to decrease exudation in several uncontrolled trials and analyses (22,23). However, benefits of TTT were called into question when a randomised, double-blind, placebo-controlled trial involving 303 patients published in 2002 failed to show a statistical difference between it and sham treatment (24). Intravitreal injection of steroids such as triamcinolone acetonide is also used to

slow progression of wet AMD (25). In addition to having angiostatic properties that cause recession of the CNV membrane, triamcinolone suppresses the chronic inflammation present in Ruysch's complex. Preclinical studies demonstrated inhibition of laser-induced neovascularisation (26,27). A non-randomised controlled clinical intervention study following patients receiving both the intravitreal injection and placebo for several months saw significant improvements in visual acuity at one and three months (28). However, long term follow-up failed to confirm the benefits of this treatment over placebo. These findings echoed those of a randomised, placebo-controlled clinical trial previously completed (29). In addition to the questionable benefit of these injections, there is also a significant risk of eye-related side effects including endophthalmitis, cataract formation and increases in intraocular pressure (30). Despite this, intravitreal corticosteroids are commonly used in wet AMD (3).

The benefit of photodynamic therapy (PDT) in the treatment of exudative AMD, in contrast, has been demonstrated in numerous randomised, placebo-controlled trials (31,32). This treatment consists of the intravenous administration of verteporfin (trade name Visudyne), a light-sensitising dye which becomes concentrated in the rapidly dividing cells of the CNV membrane, followed by irradiation of the area with a diode laser, using fluorescein angiography to visualise the CNV membrane. The laser activates the verteporfin dye causing the release of free radicals that damage the endothelium of the CNV membrane and cause thrombosis of its vessels, thus selectively destroying the membrane while leaving the surrounding normal retina unharmed (1). While the procedure does create a small scotoma, it is far less than would result from the disease being left untreated. However, as with the treatments described above, the benefit of PDT lies only in its ability to slow down the rapidly progressive course of exudative AMD (3), and CNV membrane recurrence is common (1).

Anti-Angiogenic Treatments

Unquestionably, anti-angiogenic therapy is the most revolutionary treatment for exudative AMD that has emerged to date .

Pegaptanib

Pegaptanib sodium was the first of the anti-VEGF drugs to win the approval of the United States Food and Drug Administration (FDA) for the treatment of wet AMD (33). An inhibitor of VEGF-165 (the most important of the five VEGF isoforms present in the human eye), it is injected into the vitreous humor of the eye. Approval from the European Medicines Agency (EMA) came in 2006 (33) following the VISION Study Group's two randomised, multi-centre, double-blind trials that demonstrated a 27% treatment benefit of pegaptanib therapy over PDT (2,34). The groundbreaking nature of this approach to AMD treatment, however, lay in the finding that it gave rise to an increase in visual acuity from baseline in more than 20% of those treated (1,34). As all other treatments options serve only to slow progression of the disease, the advent of a therapy

that can potentially cause regression of neovascularisation is inspiring, and the area of anti-angiogenesis is being investigated with vigour. In spite of this statistical success, however, pegaptanib does not arrest vision loss in many patients, raising doubts in some regarding its clinical benefits (3,35). An answer to this problem lay in the development of ranibizumab, a mouse/human monoclonal antibody fragment, demonstrating pan-blockade of all forms of VEGF (1,19).

Ranibizumab

The ANCHOR Study Group (ANti-VEGF Antibody for the Treatment of Predominantly Classic CHORoidal Neovascularization in AMD) demonstrated the significant efficacy of ranibizumab with a randomised, double-blind, multi-centre study (36). Ninety-five percent of treated eyes did not experience significant progression of disease (defined as the loss of more than three lines on the standard visual acuity chart) at one year compared to 62% of controls (who were undergoing PDT). In contrast, the VISION Study Group (The VEGF Inhibition Study in Ocular Neovascularisation) had found that disease progression was prevented in only 70% of eyes treated with pegaptanib compared to 55% of controls (also undergoing PDT) (34). In addition to this triumph, an improvement in visual acuity from baseline was seen in 34% of eyes treated with ranibizumab compared 5% of controls (36). The drug, administered as monthly intravitreal injections, was approved for the treatment of wet AMD by the FDA in June 2006 and by the EMA in January 2007 (33).

Bevacizumab

Currently, interest in the use of the full-length anti-VEGF mouse/human antibody bevacizumab is growing. This is fuelled in no small part by the significantly lower cost of the whole antibody (37,38), particularly following controversy that erupted in 2007 and forced the National Institute for Health and Clinical Excellence in the UK to review its final decision regarding the eligibility of ranibizumab for National Health Service funding (39). Bevacizumab, which has been licensed for the treatment of various cancers since 2004 (40), was first evaluated as a possible treatment for AMD in an open-label, single-centre, uncontrolled trial which found significant increases in visual acuity after twelve weeks of intravenous administration of the drug (41). In subsequent studies, intravitreal administration has been used, resulting in a lower incidence of systemic side effects (42). Some concerns, such as the likelihood of increased antigenicity, have been raised regarding possible side effects of the whole antibody in comparison to the partial antibody ranibizumab. Several small studies, including a retrospective case series undertaken by an Irish group, have demonstrated significant benefit associated with bevacizumab (43,44). However, at present, no large-scale, randomised trials have been carried out on the efficacy of the treatment. Despite this, and despite the fact that bevacizumab has yet to be granted either EMA or FDA approval (1,45), its low cost price has led to it being commonly used in the treatment of exudative AMD worldwide.

CONCLUSION

The face of age-related macular degeneration is changing rapidly with the recent advent of exciting new treatments for the severe exudative form and with novel treatments being investigated for the more common non-exudative form. Certainly, further research is warranted with randomised clinical trials of bevacizumab being very much called for as it is potentially the most cost-effective treatment available for neovascular AMD. Recently, research has been directed toward the genetics of the disease which may provide clues to other possible lines of treatment. Current trials are investigating the possibilities of immunotherapy, anti-pigment epithelium derived growth factor therapy and macular translocation surgery amongst others. We are entering into a new era of interest and enthusiasm for research into this disease. We can assure ourselves that the situation is growing brighter for those who, a mere ten years ago, would have been facing no vision for the future.

REFERENCES

- Morris B, Imrie F, Armbrecht AM, Dhillon B. Age-Related Macular Degeneration and Recent Developments: New Hope for Old Eyes? *Postgrad. Med. J.* 2007;83:301-6
- Macugen approved for treatment of wet AMD. *Ir. Pharm.* 2006;8:39
- Smith T, Lee L. Age related macular degeneration – new developments in treatment. *Aust. Fam. Physician.* 2007;36:359-61
- DeJong P. Age-related macular degeneration. *N. Engl. J. Med.* 2006;355:1474-85
- Boulton M, Moriarity P, Jarvis-Evans J, Marcyniuk B. Regional variation and age-related changes of lysosomal enzymes in the human retinal pigment epithelium. *Br. J. Ophthalmol.* 1994;78:125-9
- Curcio CA, Millican CL, Allen KA, Kalina RE. Aging of the human photoreceptor mosaic: evidence for selective vulnerability of rods in central retina. *Invest. Ophthalmol. Vis. Sci.* 1993;34:3278-96
- Van der Schaft TL, Mooy CM, De Bruijn WC, Oron FG, Mulder PG, De Jong PT. Histologic features of the early stages of age-related macular degeneration: a statistical analysis. *Ophthalmology.* 1992;99:278-86
- Umeda S, Suzuki MT, Okamoto H et al. Molecular composition of drusen and possible involvement of anti-retinal autoimmunity in two different forms of macular degeneration in cynomolgus monkey. *FASEB J.* 2005;19:1683-5
- Ramrattan RS, Van der Schaft TL, Mooy CM, De Bruijn WC, Mulder PG, De Jong PT. Morphometric analysis of Bruch's membrane, the choriocapillaries, and the choroids in aging. *Invest. Ophthalmol. Vis. Sci.* 1994;35:2857-64
- Gass JD. Pathogenesis of disciform detachment of the neuroepithelium. *Am. J. Ophthalmol.* 1967;63:S1-139
- Ng EWM, Adamis AP. Targeting angiogenesis, the underlying disorder in neovascular age-related macular degeneration. *Can. J. Ophthalmol.* 2005;40:352-68
- Cohen SY, Darmon J et al. Types of choroidal neovascularisation in newly diagnosed exudative age-related macular degeneration. *Br. J. Ophthalmol.* 2007;91:1173-6
- Richer S, Stiles W, Statkute L. Double-masked, placebo-controlled, randomized trial of lutein and antioxidant supplementation in the intervention of atrophic age-related macular degeneration: the Veterans Lutein Antioxidant Supplementation Trial (LAST) study. *Optometry.* 2004;75:216-30
- Richer S, Devenport J, Lang JC. LAST II: Differential temporal responses of macular pigment optical density in patients with atrophic age-related macular degeneration to dietary supplementation with xanthophylls. *Optometry.* 2007;78:213-9
- Khanifar AA, Bearably S, Cousins SW. Treatment of dry AMD: the next frontier. *Retinal Physician.* 2007
- Pulido JS, Sanders D, Klingel R. Rheophoresis for age-related macular degeneration: clinical results and putative mechanism of action. *Can. J. Ophthalmol.* 2005;40:332-40
- RHEOVision more than doubles the size of its Toronto Patient Treatment Centre to become North America's largest facility for treating dry age-related macular degeneration (AMD). Canadian Health Reference Guide. 2008; http://www.chrgonline.com/news_details.asp?ID=38138
- Study of fenretinide in the treatment of geographic atrophy associated with age-related macular degeneration. U.S. National Institutes of Health ClinicalTrials.gov. 2008; <http://www.clinicaltrials.gov/ct/show/NCT00429936?order=1>
- Waisbourd M, Loewenstein A, Goldstein M, Leibovitch I. Targeting Vascular Endothelial Growth Factor. *Drugs Aging.* 2007;24:643-62
- Macular Photocoagulation Study Group. Argon laser photocoagulation for neovascular maculopathy. Three year results from randomized clinical trials. *Arch. Ophthalmol.* 1986;104:694-701
- Mruthyunjaya P, Stinnett SS, Toth CA. Change in visual function after macular translocation with 360 degrees retinectomy for neovascular age-related macular degeneration. *Ophthalmology.* 2004;111:715-24
- Thach AB, Sipplerley, Dugel PU et al. Large-spot size transpupillary thermotherapy for the treatment of occult choroidal neovascularisation associated with age-related macular degeneration. *Arch. Ophthalmol.* 2003;121:817-20
- Algvere PV, Libert C, Lindgrade G, Seregard S. Transpupillary thermotherapy of predominantly occult choroidal neovascularisation in age-related macular degeneration with 12 months follow-up. *Acta. Ophthalmol. (Copenh).* 2003;81:110-7
- TTT4CNV clinical trial. Optimed. <http://www.optimed.com.au/TTT4CNV.htm>.
- Nadar N. Clinical trials show promise of intravitreal steroids, other therapies for retinal diseases. *Ocular Surgical News.* 2004;22:28-30
- Edelman JL, Castro MR. Quantitative image analysis of laser-induced choroidal neovascularisation in rat. *Exp. Eye Res.* 2000;71:523-33
- Jonas JB, Degenring FR, Kreissig I, Friedemann T, Akkoyun I. Exudative age-related macular degeneration treated by intravitreal triamcinolone acetonide. A prospective comparative nonrandomised study. *Eye.* 2005;19:163-70
- Gillies MC, Simpson JM, Luo W et al. A randomized clinical trial of a single dose of intravitreal triamcinolone acetonide for neovascular age-related macular degeneration: one-year results. *Arch. Ophthalmol.* 2003;121:667-73
- Ng EWM, Adamis AP. Targeting angiogenesis, the underlying disorder in neovascular age-related macular degeneration. *Can. J. Ophthalmol.* 2005;40:352-368
- Ciulla TA, Criswell MH, Danis RP et al. Choroidal neovascular membrane inhibition in a laser treated rat model with intraocular sustained release triamcinolone acetonide microimplants. *Br. J. Ophthalmol.* 2003;87:1032-7
- TAP Study Group. Photodynamic therapy of subfoveal choroidal neovascularisation in age-related macular degeneration with verteporfin: one-year results of 2 randomised clinical trials – TAP report. *Arch. Ophthalmol.* 1999;117:1329-45
- VIP Study Group. Verteporfin therapy of subfoveal choroidal neovascularisation in age-related macular degeneration: two-year results of a randomised clinical trial including lesions with occult with no classic choroidal neovascularisation. *Am. J. Ophthalmol.* 2001;131:541-60
- Medscape Medical News. <http://www.medscape.com>
- Gragoudas EV, Adamis AP, Cunningham ET, Feinsod M, Guyer DR. The VEGF Inhibition Study in Ocular Neovascularisation (VISION) Clinical Trial Group: Pegaptanib for neovascular age-related macular degeneration. *N. Engl. J. Med.* 2004;351:2805-16
- Joussen AM, Lehmann W, Hilgers RD, Kirchhof B. Is significant relevant? Validity and patient benefit of randomized controlled clinical trials on age-related macular degeneration. *Surv. Ophthalmol.* 2007;52:266-78
- Brown DM, Kaiser PK, Michels M et al. The ANCHOR Study Group: Ranibizumab versus verteporfin for neovascular age-related macular degeneration. *N. Engl. J. Med.* 2006;355:1432-44
- Steinbrook R. The price of sight – ranibizumab, bevacizumab and the treatment of macular degeneration. *N. Engl. J. Med.* 2006;355:1409-12
- Raftery J, Clegg A, Jones J, Chuen Tan S, Lotery A. Ranibizumab (Lucentis) versus bevacizumab (Avastin): modelling cost effectiveness. *Br. J. Ophthalmol.* 2007;91:1244-46
- White C. NICE delays decision on drugs for macular degeneration. *B.M.J.* 2007;335:319.
- Folkman J. Bevacizumab: anti-angiogenesis success story. *Community Oncology.* 2007;4:290-2
- Michels S, Rosenfeld PJ, Puliafito CA, Marcus EN, Venkatraman AS. Systemic bevacizumab (Avastin) therapy for neovascular age-related macular degeneration twelve-week results of an uncontrolled open-label clinical study. *Ophthalmology.* 2005;112:1035-47
- Rich RM, Rosenfeld PJ, Puliafito CA et al. Short-term safety and efficacy of intravitreal bevacizumab (Avastin) for neovascular age-related macular degeneration. *Retina.* 2006;26:495-511
- Cleary CA, Jungkim S, Ravikumar K, Kelliher C, Acheson RW, Hickey-Dwyer M. Intravitreal bevacizumab in the treatment of neovascular age-related macular degeneration, 6- and 9-month results. *Eye.* 2008;22:82-6
- Bashshur ZF, Haddad ZA, Schakal A, Jaafar RF, Saab M, Noureddin BN. Intravitreal bevacizumab for treatment of neovascular age-related macular degeneration: a one-year prospective study. *Am. J. Ophthalmol.* 2008 [e-pub ahead of time]
- AMD Alliance International. "Statement on Avastin" Retinal Physician. July 2006