

# A Case of Fournier's Gangrene

Elaine Neary, 4th Year Medicine

## ABSTRACT

Fournier's gangrene is a rare, necrotising fasciitis of the genitals and perineum caused by a mixture of aerobic and anaerobic microorganisms. The complications of this synergistic infection are multiple organ failure and death. I report a case of a gentleman who presented to Accident and Emergency with gangrenous and necrotic penile, scrotal and perineal areas. Due to the aggressive nature of this condition, early diagnosis is crucial. Treatment involves extensive soft tissue debridement and broad-spectrum antibiotics. Despite appropriate therapy, mortality is high.

## INTRODUCTION

Fournier's gangrene is an uncommon, rapidly progressive infection of the male genital, perineal and perianal regions with occasional cranial extension to the abdominal wall. It is characterised by a synergistic, necrotising fasciitis leading to the thrombotic occlusion of small subcutaneous vessels and the development of gangrene.<sup>1</sup> There are two types. Type I is due to a mixture of aerobic and anaerobic organisms usually following an abdominal operation or associated with diabetes mellitus.<sup>2</sup> Type II is due to Group A *Streptococcus* synergistic with a second organism (*Staphylococcus aureus*, coliforms, *Bacteroides* spp.).<sup>2,3</sup> The majority of patients with Fournier's gangrene are immunocompromised and thus the primary wound might have been minor or might have arisen from an otherwise uneventful operation.<sup>3,4</sup> Malignant disease, obesity, diabetes mellitus, peripheral vascular disease, local trauma, urethral stricture and perianal disease have been cited as the main predisposing factors.<sup>5</sup> Early presentation and diagnosis, supportive measures and the use of broad-spectrum antibiotics with prompt and aggressive surgical debridement remain the cornerstone of management.<sup>6</sup> In spite of these advancements in management, mortality is still high and averages 20-30 percent.<sup>4</sup>

## CASE REPORT

A sixty-three year old gentleman was admitted by ambulance to the Accident and Emergency Department of a university teaching hospital in Dublin, Ireland, in January, 2005. He had been found lying in faeces in his room, which was fly-infested. No medical, surgical or family history was available, nor knowledge of any drug allergies. Collateral social history revealed that he lived on his own. Initial vital signs indicated that the patient was hypothermic (30.1°C), hypotensive (54/34mm Hg), bradycardic (45 beats per minute) and dehydrated. He was moving all four limbs and scored 13/15 on Glasgow Coma Scale.

Physical examination of his abdomen revealed a palpable bladder. Perineal examination revealed the entire penile skin to be gangrenous and necrotic. His scrotum was hard, swollen, erythematous and the left hemiscrotum was gangrenous. The perineal area was cellulitic and gangrenous. The inguinal area was swollen and cellulitic bilaterally, with a necrotic ulcer and lymphadenopathy. Digital rectal examination revealed a firm prostate, laena and small polyps. No other masses were palpable.

## Investigations

Table 1.

### Full Blood Count and Platelets

		Reference Ranges
White Cell Count	*30.5 x10 <sup>9</sup> /l	(4.0 – 11.0)
Neutrophils	*29.0 x10 <sup>9</sup> /l	(2.0 – 7.5)
Lymphocytes	*1.2 x 10 <sup>9</sup> /l	(1.5 – 3.5)
Monocytes	0.3 x 10 <sup>9</sup> /l	(0.2 – 0.8)
Eosinophils	0.0 x 10 <sup>9</sup> /l	(0.0 – 0.4)
Basophils	0.0 x 10 <sup>9</sup> /l	(0.0 – 0.1)
Red Cell Count	*4.23 x 10 <sup>12</sup> /l	(4.60 – 5.70)
Haemoglobin	13.7 g/dl	(13.5 – 18.0)
Haematocrit	*0.384 (Ratio)	(0.430 – 0.510)
Mean Cell Volume	90.8 fl	(83.0 – 99.0)
Mean Cell Haemoglobin Content	*35.7 g/dl	(30.8-34.6)
Red Cell Distribution Width	13.6	(11.0-15.0)
Platelets	434 x 10 <sup>9</sup> /l	(140-450)

### Renal Profile

Urea	*90.0 mmol/L	( 3.0 – 7.0 )
Sodium	*128 mmol/L	( 135 – 145 )
Potassium	*7.8 mmol/L	( 3.5 – 5.0 )
Creatinine	*894 umol/L	( 50 – 115 )
Bicarbonate	Not available	

### Liver Profile

Total Protein	73 g/L	( 60 – 80 )
Albumin	*25 g/L	( 35 – 50 )
Total Bilirubin	10 umol/L	( 0 – 17 )
Alkaline Phosphatase	*441 IU/L	( 40 – 120 )
Gamma – GT	*156 IU/L	( 10 – 55 )
LDH	*595 IU/L	( 230 – 450 )
AST	*72 IU/L	( 7 – 40 )

Wound Swab of Scrotum

Culture	Ampicillin	Ciprofloxacin	Gentamicin
+++A.lwofii	Sensitive	Sensitive	Sensitive

*Note: Further swab revealed the wound to be MRSA positive, which was likely to represent a nosocomial complication.*

Blood Film

Neutrophil leukocytosis
Neutrophils contain toxic granular echinocytes (burr cells)
Lymphocyte morphology appears normal
Echinocytes could represent a storage artefact, or associated liver or renal disease

**Hospital Course**

The Urology team established the diagnosis of Fournier's gangrene of the penile skin and subcutaneous tissue and perineum, complicated by acute urinary retention, acute renal failure and septic shock. It was hypothesised that the infection started as a small perianal collection which progressed. He was treated with broad-spectrum antibiotics (penicillin, gentamicin and metronidazole) and debridement of the necrotic skin with near total resection of the penis. The team inserted a suprapubic urinary catheter, a faecal drainage tube and a fine bore nasogastric-feeding tube. A tracheostomy was created to facilitate airway and pulmonary management. Following surgery, the patient was transferred to the ICU for monitoring and support. He required dialysis, inotropic support and morphine infusions. Postoperatively, wound care was performed with twice daily dressing changes with Dakin's solution. One week later, the patient returned to theatre in order to establish if any necrotic tissue remained. The rectus sheath was found to be partially gangrenous. Hydrogen peroxide was used intraoperatively to destroy the gangrenous tissue through the formation of free radicals. Due to extensive blood loss his haemoglobin dropped to 7.3g/dl and blood pressure to 81/24 mm Hg. The patient received two units of blood and intravenous Hartmans solution. Several litres of normal saline were used intraoperatively to wash out the wound in order to minimise bacterial counts. The extensive wound was initially packed, with the intention of closing later by means of skin grafting. Meanwhile, the testes were placed in subcutaneous pockets in the upper border of the wound for coverage.

DISCUSSION: FOURNIER'S GANGRENE

Gangrene is defined as the local death of soft tissues due to disease or injury. The dead tissue is nearly always colonised by bacteria. Gangrene can be of two types:<sup>7</sup>

- 1) Non infected/dry
- 2) Infected or wet/gas gangrene.

Gas gangrene is a rapidly progressive infection with a high mortality rate that has been recognised for much of medical history. Hippocrates described necrotising infections that caused 'flesh, gnaw and bones to fall away in great quantity.'<sup>8</sup> There are a number of subdivisions including: Clostridium cellulites, Clostridium myonecrosis and necrotising fasciitis. However, these entities represent part of a continuum, not all of which are due to clostridial species. Fortunately, deep soft tissue infections from gas-forming pathogens are relatively unusual and clinicians encounter this problem infrequently during their surgical careers.<sup>8</sup> These infections can infect multiple systems in the body including the skin, exocrine and cardiovascular systems. There is no gender, age or genetic predisposition, although they are more common in debilitated elderly patients with compromised immune systems.<sup>5</sup>

Necrotising fasciitis is a fulminant, rapidly progressive spreading infection. Widespread tissue destruction and necrosis of fat and fascia with overlying secondary necrosis of skin are characteristic of the infection (2-3 cm/hour at its most severe). Jean Alfred Fournier, a French venerologist, described a subgroup of necrotising fasciitis in 1883.<sup>9</sup> Originally, it was thought to be an idiopathic infection of healthy males. However, modern use of the term Fournier's gangrene has been expanded to include all perineal necrotising infections in both men and women.<sup>8</sup> The majority of infections documented occur in diabetic men aged 50 to 70 years.<sup>9</sup> It is a serious condition characterised by cellulitis of the scrotal skin leading to subcutaneous necrosis, all of which are preceded by subcutaneous crepitations. The testes are unaffected.<sup>3</sup> Fournier's gangrene can be classified as a synergistic necrotising sepsis if the tissues of the abdominal wall below the deep fascia, such as the anterior sheath of the rectus muscle, are involved.

## Signs and Symptoms

The illness begins with a prodromal period of genital discomfort and pruritis followed by sudden onset of perineal pain out of proportion to the stimulus applied.<sup>5,8</sup> However, as the gangrene progresses this pain is replaced by anaesthesia.<sup>8</sup> Initially, the skin may appear to be normal and the extent of the subdermal gangrene may not be apparent.<sup>3,8</sup> This is important because it may delay diagnosis as the infection is centered at the fascial level. Progression through the fascial layers results in deep tissue necrosis and gangrenous skin changes, resulting in drainage of the affected area and demarcation between viable and dead tissue.<sup>5,8</sup> A by-product of anaerobic metabolism is the formation of crepitus, composed of hydrogen, hydrogen sulphide, nitrogen and nitrous oxide, which may be detected on x-ray, thus indicating the presence of dead tissue.<sup>8,9</sup> All of these signs are associated with a foul odour. There is rapid development of severe toxæmia with associated signs, for example, pyrexia with or without hypothermia, leukocytosis, thrombocytopenia, raised blood urea and nitrogen, tachycardia, hypotension and reduced urine output.<sup>8,9</sup> This may occur in just a few hours progressing to organ failure and death so the admitting physician must have a high index of suspicion when assessing the case.<sup>8</sup>

## Causes

One of the most important causes of this infection is poor hygiene, which was evident in the case of the patient described above (Figure 1). Usually it is due to a less aggressive, more routine infectious process through some point of entry involving the colon, urinary tract, prostate or anorectal area, for example, a skin abscess, incarcerated inguinal hernia or fistulous tract.<sup>5,8</sup> It can also proceed from cellulitis or traumatic injury involving cutaneous structures in the perianal region.<sup>8</sup> A primary infectious focus can be determined in 95 percent

of cases.<sup>6</sup> Obstetric events such as vaginal deliveries with episiotomies and Caesarean section, carcinoma of the large intestine, hematological malignancies, severe neutropenia and burns have also been implicated.<sup>8</sup> Predisposing factors for the development of necrotising soft tissue infections include: poor perfusion, hypertension, renal insufficiency, trauma, diabetes mellitus, malnutrition, immune suppression, cigarette smoke, intravenous drug abuse, obesity and spinal cord injury.<sup>8,10</sup> Old age itself is not a predisposing factor; however, elderly patients with poor self care and poor nutritional status are more susceptible to Fournier's gangrene and have a poorer prognosis.<sup>5</sup>

## Diagnosis

Differential diagnosis includes cellulitis, balanitis, orchitis, epididymitis, torsion, strangulated hernia and benign scrotal oedema.<sup>1</sup> A range of investigations can combine to confirm the diagnosis, however it is usually a clinical diagnosis and the role of diagnostic imaging is limited. A full blood count is appropriate which in this case will reveal anaemia and leukocytosis. Renal profile is impaired with high urea and creatinine, which is typically secondary to septic shock. Coagulopathies, such as disseminated intra-vascular coagulopathy, secondary to sepsis/septic shock may also be seen. A mid-stream urine sample is taken to exclude urinary tract infection. The source of infection should be investigated by whatever means necessary. An intravenous pyelogram, barium enema, sigmoidoscopy and/or cystoscopy may be appropriate and the underlying cause should be treated.<sup>3</sup> Tissue biopsies and pus are sent for culture and sensitivity tests to detect gas-producing microorganisms. Synergy and interaction among organisms is seen in Fournier's gangrene, resulting in increasing virulence and local vascular thrombosis.<sup>3</sup> Streptococci release toxins such as streptokinase and hyaluronidase which cleave the fascial planes and allow the

Physiologic Variable/ Point Assignment	High Abnormal Values				Normal	Low Abnormal Values			
	+4	+3	+2	+1	0	+1	+2	+3	+4
Temperature (°C)	> 41	39-40.9	-	38.5-39	36-38.4	34-35.9	32-33.9	30-31.9	<29.9
Heart rate	> 180	140-179	110-139	-	70-109	-	55-69	40-54	<39
Respiratory rate	> 50	35-49	-	25-34	12-24	10-11	6-9	-	<5
Serum Sodium (mmol/L)	> 180	160-179	266-159	350-354	130-149	-	120-129	111-119	<110
Serum Potassium (mmol/L)	> 7	6-6.9	-	5.5-5.9	3.5-5.4	3-3.4	2.5-2.9	-	<3.5
Serum Creatinine (mg/100/ml x 2 for acute renal failure)	> 3.5	2-3.4	1.5-1.9	-	0.6-1.4	-	<0.6	-	-
Hematocrit	> 60	-	50-59.9	46-49.9	30-45.9	-	20-29.9	-	<20
WBC (total/mm <sup>3</sup> x 1000)	> 40	-	20-39.9	15.19.9	3-14.9	-	1-2.9	-	<1
Serum bicarbonate (venous, mmol/L)	> 52	41-51.9	-	32-40.9	22-31.9	-	18-21.9	15.17.9	<15

**Table 2.** Fournier's gangrene severity index. Reproduced with permission of Lippincott Williams and Wilkins from Laor E, Palmer LS, Toila BM et al: Outcome prediction with Fournier's Gangrene. *J Urol* 154: 89-92, 1995.

infection to spread rapidly.<sup>7</sup> The clinical picture is similar regardless of the bacterial species involved. The administration of antibiotics prior to culture can alter these results. A frozen section is useful for visualising soft tissue necrosis and dense infiltration of the involved area with polymorphonucleocytes. MRI will show oedema but is not necessary for diagnosis.

**Treatment**

These infections are a surgical emergency; a delay in treatment is associated with a significantly higher mortality rate. Radical debridement should be carried out, aggressively removing all necrotic tissue and any marginally perfused tissue, dissecting through all the fascial planes. Under normal circumstances, it takes significant force to separate soft tissues from fascia. However, if a blunt probe slides through this plane effortlessly, it is indicative of necrotising fasciitis. Debridement should be continued until all remaining tissues are adherent and viable.<sup>8</sup> However, this can pose a problem if the necrosis is extensive. In the case above, the rectus sheath was found to be partially gangrenous during the second operation, but its removal was not feasible as to do so would entail great risk to the patient. As a rule, the penis, testes, bladder and rectum are spared if possible. Spirnak *et al.* reported that patients who undergo multiple

operations have greater mortality.<sup>11</sup> The authors believed that was due to a greater extent of disease in these patients. Appropriate intravenous broad-spectrum antibiotics which are effective against both anaerobic gram-negative and facultative aerobic organisms are important therapeutic adjuvants, but are not substitutes for proper surgical debridement. Empirical therapy is given initially which can then be modified on the basis of culture and sensitivity tests. Therapeutic drug monitoring is appropriate. The patient's results should be reviewed daily and creatinine phosphokinase (CPK) levels should be obtained to monitor for myonecrosis. As mentioned above, the patient was receiving enteral nutrition. Patients with large open wounds should be fed at a rate of 1.5 to two times greater than the basal requirement. Nutritional parameters such as albumin, prealbumin and transferrin should be monitored to assure proper caloric intake. The use of hyperbaric oxygen therapy is debatable as its therapeutic value is unclear.<sup>8</sup> The wound is closed later with skin grafting. Previously, unmeshed split-thickness skin grafts were used, but there is a vogue for the use of meshed split-thickness skin grafts due to 100 percent uptake rates, safety and efficacy.<sup>12, 13</sup> The aim is to restore function quickly and provide a good cosmetic outcome.<sup>12</sup> The resultant scar may predispose patients to squamous cell carcinoma after a long latent

Author	Year	Patients	Overall Mortality	Mortality with Early Débridement	Mortality with Delayed Débridement	Comment
Wang and Shih	1992	33	33%	20%	75%	Extremities only
Cartwright <i>et al.</i>	1995	6	33%			All strep*
Tsai <i>et al.</i>	1995	54	22%	0%	40%	
Shupak <i>et al.</i>	1995	37	32%	with HBO; (Hyperbaric Oxygen Therapy) 36%	(without HBO Therapy) 25%	
Moss, Musemecheaa and Kosloske.	1996	20	25%	0%	100%	Paediatric
Lille <i>et al.</i>	1996	29	14%	6%	25%	
Kaul <i>et al.</i>	1997	77	34%			Age, hypotension, bacteraemia correlated with mortality/all strep*
Bilton <i>et al.</i>	1998	68	15%	4%	38%	
Elliott, Kufera and Myers	2000	182	25%			Bacteraemia, delayed surgery, organ dysfunction correlated with mortality
Brandt, Corpron and Wahl	2000	37	24%			Age, ventilator use correlated with mortality
Futes-Morales <i>et al.</i>	2002	39	18%			Paediatric
Sharma, Khatib and Fakih	2002	9	33%			Toxic shock predicted mortality/all strep*
Dahl <i>et al.</i>	2002	7	71%			Toxic shock predicted mortality/all strep*
<i>Total</i>		598	25%	6%	40%	

**Table 3.** Mortality of Necrotising Fasciitis in Series Published After 1990.

\* All patients in this selected series had a streptococcal infection.

^ All patients in this series were younger than 18 years.

From: Cameron JL. *Current Surgical Therapy* 8<sup>th</sup> edition, Philadelphia: Elsevier Mosby; 2004: 1079-1085

period. This time lag differentiates it from other scar carcinomas or Marjolin's ulcer.<sup>14</sup>

### Expected Course/Prognosis

Fournier's gangrene is a life threatening illness requiring emergency surgery, despite which the patient may still not survive. Mortality rates as high as 20 to 30 percent have been described in some studies.<sup>4</sup> Certain factors influencing the survival of these patients, primarily relating to the patient's metabolic status and the extent of the disease, were evaluated by Laor *et al.* from which the Fournier's gangrene severity index (FGSI) was formulated.<sup>15</sup> In the FGSI, nine parameters are measured and the degree of deviation from normal is graded from 0 to 4. The individual values are summed to obtain the FGSI score (FGSIS). These parameters are: temperature, heart rate, respiratory rate, levels of serum sodium, potassium, creatinine and bicarbonate, haematocrit and leukocyte count (Table 2). In a study by Yenyol *et al.* the accuracy of this index was tested. They found that the duration of symptoms before presentation was statistically important. Of the nine parameters, temperature, heart rate and respiratory rate were considered to be the most important by these

authors. In patients who died, however, all the parameters were abnormal. The authors also found that lower serum albumin and total protein levels indicated the degree of debilitation and a poor prognosis. However, early diagnosis and treatment and the arrest of the gangrene at an early stage markedly improve outcome. The mortality from these infections has dropped significantly in the last century.<sup>8</sup> The most common error in the management of these lesions is delayed or inadequate surgical debridement. Other factors associated with increased mortality in necrotising infections are advanced age, co-existent systemic sepsis and development of organ failure (Table 3). Co-morbid conditions such as cancer, renal insufficiency and congestive heart failure also contribute to an increased mortality rate.<sup>8</sup>

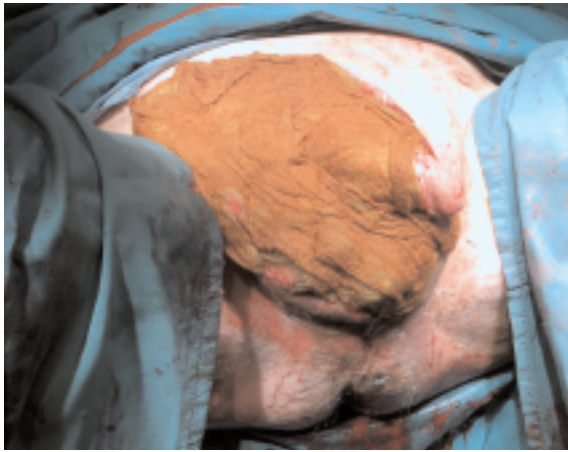
### CONCLUSION

Despite the fact that Fournier's gangrene is a rare condition, it is essential that physicians know how to recognize it. Early recognition and diagnosis, followed by emergency surgery, are the keys to treating these cases and to the prevention of systemic sepsis, potential organ failure and death.

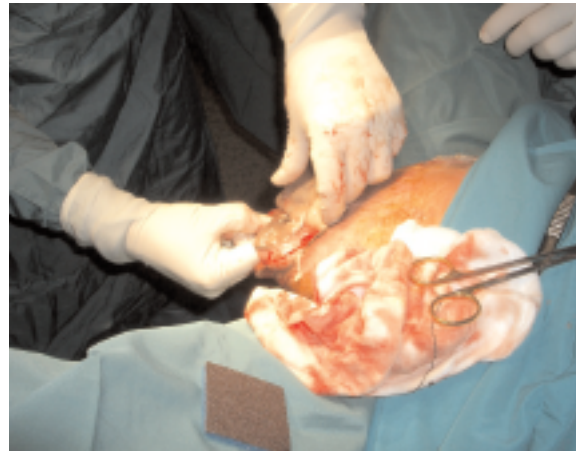
---

### REFERENCES

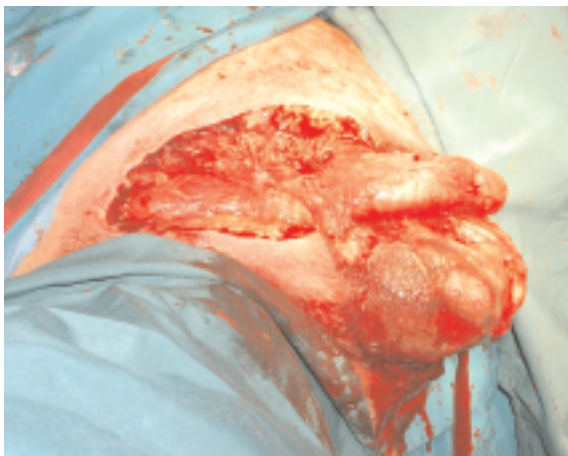
1. Patankar SP, Lalwani SK. Fournier's gangrene. *J Indian Paediatr* 2004;41:511.
2. Kumar P, Clarke M, eds. *Clinical Medicine*. 5th ed. Edinburgh: WB Saunders, 2002:66-7.
3. McLatchie GR, Leaper DJ, eds. *Oxford Handbook of Clinical Surgery*. 2nd ed. Oxford UK: Oxford University Press, 2003:53,890.
4. Pawlowski W, Wronski M, Krasnodebski IW. Fournier's gangrene. *Pol Merkurusz Lek* 2004; 17(97):85-7.
5. Yenyol CO, Suelozogen T, Arslan M, Ayder RA. Fournier's gangrene: Experience with 25 patients and the use of Fournier's gangrene severity index score. *Urology* 2004;64(2):218-22.
6. Muqim R. Necrotising fasciitis: management and outcome. *J Coll Physicians Surg Pak* 2003;13(12):711-4.
7. Henry M, Thompsen J, eds. *Clinical Surgery*. 1st ed. Edinburgh: WB Saunders, 2002:113,126.
8. Cameron JL, ed. *Current Surgical Therapy*. 8th ed. Philadelphia: Elsevier Mosby, 2004:1079-85.
9. Upport RN, Levy HM, Patel PH. Case 54: Fournier's Gangrene. *Radiology* 2003;226:115-7.
10. Vaidyanathan S, Soni BM, Hughes PL et al. Necrosis of the scrotum (Fournier's gangrene) in a spinal cord injury patient - a case study. *BMC Fam Pract* 2002;3; 20.doi10.1186/1471-2296-3-20.
11. Spirnak JP, Resnick MI, Hampel N. Fournier's gangrene: report of 20 patients. *J Urol* 1984;131:289-92.
12. Black PC, Friedrich JB, Engrav LH, Wessells, H. Meshed unexpanded split-thickness skin grafting for reconstruction of penile skin loss. *J Urol* 2004;172(3):976-9.
13. Maguina P, Palmieri TL, Greenhalgh DG. Split thickness skin grafting for recreation of the scrotum following Fournier's gangrene. Doi:10.1016/j.burns. 2003.07.001.
14. Chintamani, Shanker M, Singhal V, Singh JP, Bansal A, Saxena S. Squamous cell carcinoma developing in the scar of Fournier's gangrene-Case Report. *BMC Cancer* 2004;4:16 doi:10.1186/1471-2407-4-16.
15. Laor E, Palmer LS, Toila BM et al. Outcome prediction in patients with Fournier's gangrene. *J Urol* 1995;154:89-92.



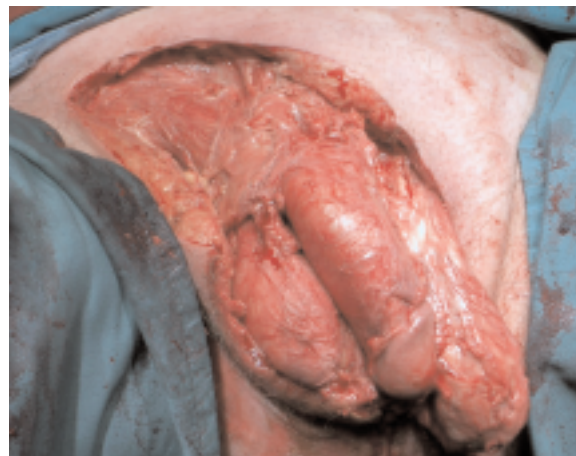(A)



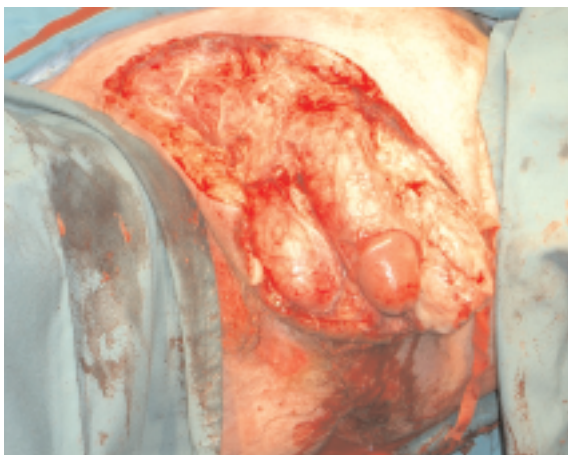
(B)



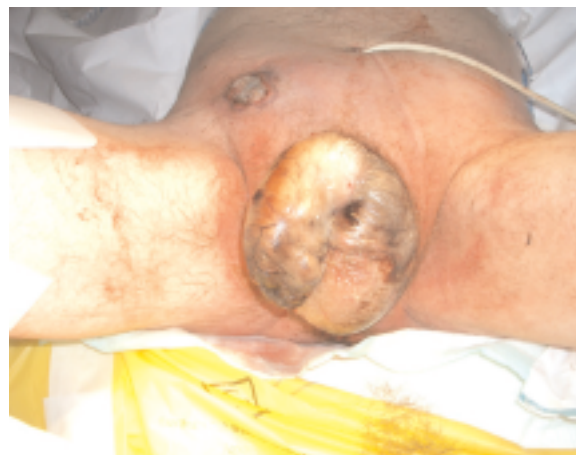(C)



(D)



(E)



(F)

**Figure (A)-(F).** Fournier's Gangrene as seen intraoperatively.\*  
\*Photos provided by Rustom Maneksha.