

# ABC's of Chest X-Rays

*Myto Duong, Peter Timoney, Ross MacNicholas, Joanne Kitchen, Mazyln Mustapha, Usha Arunasalam, all 5<sup>th</sup> Year Medicine*

## INTRODUCTION

Radiology plays an important role not only for diagnostic purposes but also in intervention. Although the field of radiology is vast and encompasses the use and interpretation of ultrasound, CT and MRI, most consultants will mainly expect medical students to be proficient at interpreting x-rays of common conditions (i.e. pneumonia, heart failure, intestinal obstruction and fractures). The aim of this paper is to provide students with a systematic way of viewing and interpreting x-rays, more specifically chest x-rays, to ensure that the major aspects are not missed. This systematic approach to x-ray interpretation is a modified and expanded version of one proposed by Talley and O'Connor in *Clinical Examination*. This paper is a summary of our group project in paediatrics and therefore the x-rays used in the article are of childhood conditions.

There are 5 basic radiographic densities, which appear on x-rays as various shades of black and white (materials of low density appear darker than objects of high density):

- black lungs (air)
- dark grey subcutaneous tissue (fat)
- light grey heart and blood vessels  
(soft tissue)
- off white clavicle and ribs (bone)
- bright white  
(metal jewellery or right and left labels)

Therefore, structures or objects can be detected on chest x-rays if they are located next to structures of different densities (i.e. white/grey heart border against a black aerated lung field). In the situation of pneumonia in which the consolidated areas of the lung(s) become more dense and similar to the density of the heart, the contrast between the densities of the two organs is lost resulting in the heart border being obscured.

Chest x-rays can be taken from different views/positions: posterior to anterior (PA), lateral, anterior to posterior (AP), decubitus, lordotic and oblique. The PA view is most commonly used because it will give a more accurate assessment of the cardiac size and the scapulae can be rotated out of the way. If possible the PA x-ray should be done with the patient standing:

- ♦to give a more physiological representation of the blood vessels and not one of distended vessels or widened mediastinum.
- ♦to facilitate the diagnosis of pneumothorax or free gas passing upwards (seen under the diaphragm).
- ♦to facilitate the diagnosis of pleural effusion with fluid pooling downwards.

In situations in which the patients are too ill to stand upright, the x-rays are taken with the patient supine via an AP film. These x-rays are most com-

monly used in intensive and coronary care units, and in the accident and emergency departments. The problem with AP films is that the mediastinum appears widened due to venous distension and magnification, which may result in misdiagnosis, and hinder the exclusion of aortic rupture in trauma cases.

Areas or structures which may be obscured on the PA film can be better viewed with a lateral x-ray. For example, the posterior segments of the lower lobes (behind the hila) and the left lower lobe of the lungs (behind the heart) can be assessed on lateral films. The lateral radiographs can also offer good views of the thoracic spine and are more sensitive for pleural effusions. Decubitus films, taken with the patient lying on their side, are occasionally used if the patients are too ill to stand and a lateral view is required. The lordotic film is one taken at an upward angle to obtain a view of the lung apices.

Chest x-rays are usually taken during inspiration but expiratory ones are useful in suspected pneumothorax and bronchial obstructions with air trapping (i.e. inhaled foreign body in a child).

When asked to interpret an x-ray, it is important that one should start by commenting on: the name and birth date of the patient whose x-ray you are presenting; the type of x-ray (PA or lateral etc.); and when it was taken. For example one could state, "This is a PA film taken on 11/02/01 of JB who was born on the 21/03/99". All of this general information can usually be found on the upper left hand corner of the x-ray film. Then place the x-ray film on a light box and take 2-3 steps back to get a proper view of the radiograph. Consultants are often very quick to pick up on one of the most commonly made mistakes by students, which is to peer at the x-ray too closely. Next a comment should be made on the technical quality of the x-ray such as:

- ♦ensuring the patient is centred on the film such that both lung apices and costophrenic angles are captured; the term used is "well centred".
- ♦ensuring that there is no rotation by checking that the spinous processes lie midway between the medial ends of the clavicles; the term used is "not rotated", or "is rotated to the right/left".
- ♦ensuring adequate penetration by checking that the vertebral bodies are just visible at the lower border of cardiac shadow. If they are too visible, it indicates an over penetrated film which results in missing low-density lesions. If the vertebral bodies are not visible (representing an under penetration), the lung fields appear falsely white. The degree of penetration is important when comparing serial x-rays used to monitor the patients progress and response to therapy. (Note that at the AMNCH Hospital, x-rays are now stored digitally and therefore technical

quality of the radiograph is less important since they can be manipulated with a click of the mouse key.)

#### THE SYSTEMATIC APPROACH TO CHEST X-RAY

The proposed system for looking at a radiograph of the chest involves remembering part of the alphabet:

- A**-airway
- B**-bone
- C**-cardiac
- D**-diaphragm
- E&F**-equal (lung) fields
- G**-gastric bubble
- H**-hilum (and mediastinum)

#### AIRWAY

- ♦ Look at the trachea and its branches: check the site, size, shape, and shadow (4 S's).
- ♦ Is it patent, or narrowed indicating stenosis or edema? Is it central? (in children it should be straight but in adults it can deviate to the right due the aortic arch)

#### BONE

- ♦ Look at and compare the bony structures paying attention to site, size, shape, shadows and borders: (clavicles, ribs, scapulae, thoracic vertebrae, and humeri).
- ♦ Any fractures? Using a pointer follow along the smooth edges of each bone looking for an interruption of the smooth line.
- ♦ Any lytic lesions? Look for discrete darker areas or a change in bone density.
- ♦ Any bony deformity? (rachitic rosary at the costochondral joints seen in rickets)
- ♦ Any extra? (cervical ribs)
- ♦ Any missing bones? (absent vertebral arches in spina bifida occulta)
- ♦ Look for lateral deviations of the vertebrae in scoliosis.

#### CARDIAC

- ♦ Take note of the cardiac site, size, shape, shadows and borders.

Site: is it located on the right or left?

Size: is it less than half the transthoracic diameter? (i.e. is the largest diameter of the heart less than half the largest diameter of the thorax)

Shape: is it ovoid with the apex pointing to the left?

Shadows: any change in density?

Borders: is it clear or well defined?

-unclear right border suggest middle lobe consolidation.

-unclear left border suggest lingular lobe consolidation.

#### DIAPHRAGM

- ♦ Look at the outline of the diaphragm; it should be clear and smooth.
- ♦ Right hemidiaphragm should be higher (2-3cm) than the left:

-highest point on the right should be in the middle of the right lung field.

-highest point on left should be slightly lateral to the middle of the left lung field (see Figure 1).

-deviation may indicate pneumothorax.

- ♦ Are the costophrenic angles well defined?
- whiteness immediately above the diaphragm indicates pleural effusion or consolidation.
- the presence of fluid will produce a meniscus (Meniscus Sign) or a concave upper border
- ♦ Is there air below each hemidiaphragm indicating bowel perforation?
- ♦ Is the diaphragm below the anterior end of the 6<sup>th</sup> rib on the right? If so, this indicates hyperinflation.

#### EQUAL (lung) FIELDS

- ♦ Divide lung fields into zones: upper, middle, and lower zones

-upper: from the apex to 2<sup>nd</sup> costal cartilage

-middle: between 2<sup>nd</sup> and 4<sup>th</sup> costal cartilage

-lower: between 4<sup>th</sup> and 6<sup>th</sup> costal cartilage

- ♦ Look for equal radiolucency (or blackness due to air filling) between the left and the right lungs zones.

- ♦ Look for any discrete or generalized grey/white shadows (described as opacity/patchy shadows)

- ♦ The horizontal fissure on the right, divides the upper and middle lobes:

-from the hilum to the 6<sup>th</sup> rib at the axillary line

- ♦ Look for vascular markings:

-indicating pulmonary hypertension pruning

- ♦ More specifically look for:

-Air bronchograms are visible air-filled bronchi, outlined by surrounding consolidation.

-Bat's wing distribution describes one of two patterns of consolidation (the other pattern being lobar); refers to the bilateral opacification spreading from the hilar regions into the lungs (sparing the peripheral lung areas) signifying extensive alveolar disease. The causes of bat's wing are: pulmonary edema in heart failure, fluid overload, hypoproteinaemia, blood transfusion reaction, and others.

-Reversed bat's wing distribution are alveolar opacification in the peripheral lung fields with sparing of the central areas seen in fat embolism 1-2 days following a bone fracture.

-Kerley A, B, and C lines which are fine lines running through the lungs representing thickened connective tissue septae seen in interstitial pulmonary edema.

- ♦ Kerley A lines are found in the upper lobes.

- ♦ Kerley B lines are short (1-2 cm) horizontal line in the lower lobes.

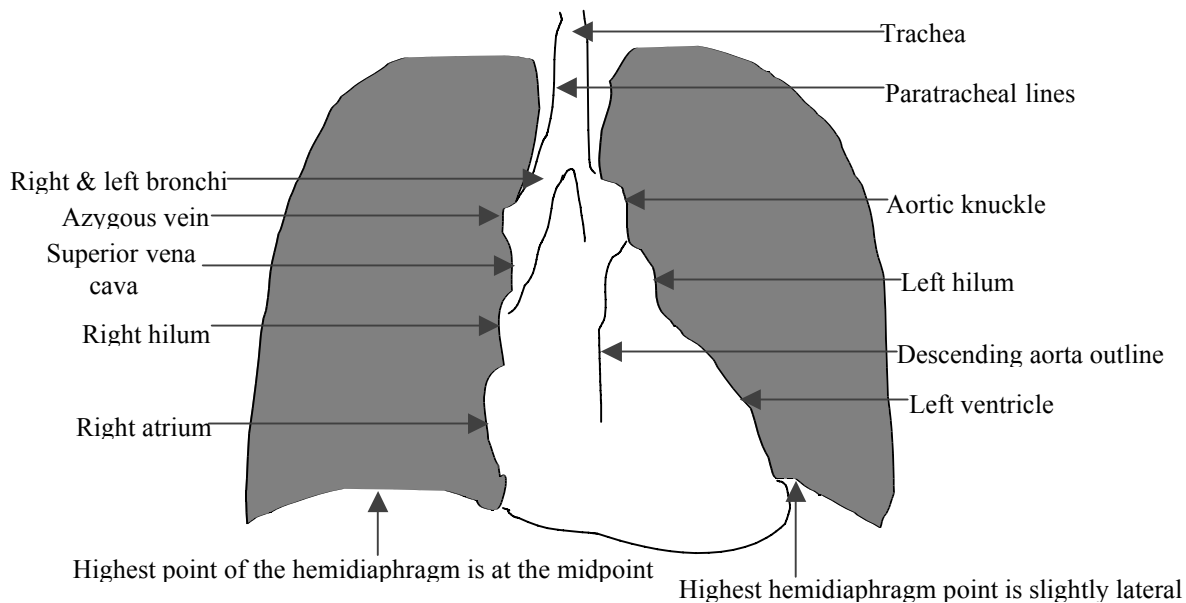
- ♦ Kerley C lines are diffusively distributed through the entire lung.

These Kerley lines may be associated with cardiac enlargement and pleural effusions.

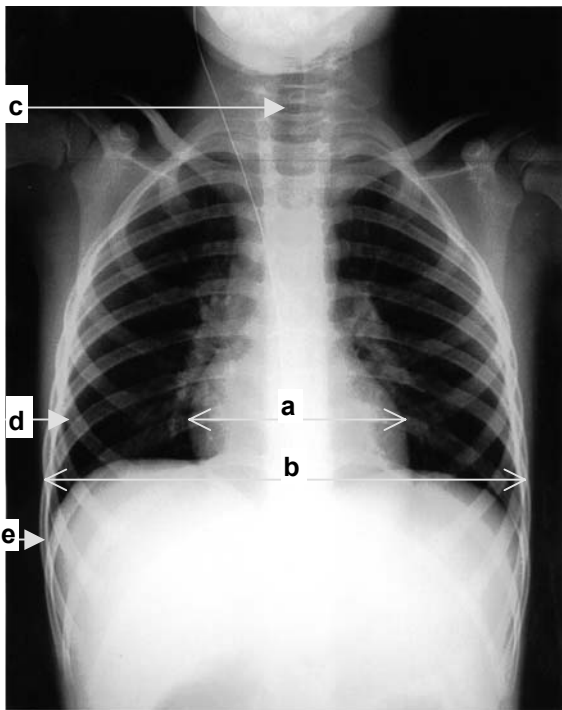
#### GASTRIC FUNDUS

- ♦ Look for an air bubble under the left hemidiaphragm.

- ♦ Look for diaphragmatic hernia on the right or left.

**Diagram 1:** Key landmarks on a chest x-ray**Figure 1:** A normal chest x-ray

(a) cardiac diameter; (b) transthoracic diameter; (c) trachea; (d) 5th anterior rib; (e) right costophrenic angle.



(loops of air filled bowels above the diaphragm)

## HILUM AND MEDIASTINUM

- ♦ Look at the hilum (which consists of main bronchus and pulmonary arteries) -the left should be higher than the right.
- ♦ Compare the convex shapes and densities on both sides.
- ♦ The paratracheal lines are thin lines of the right and left tracheal margins which are thickened in lymphadenopathy.

## SOME EXAMPLES OF CHEST X-RAY DESCRIPTIONS

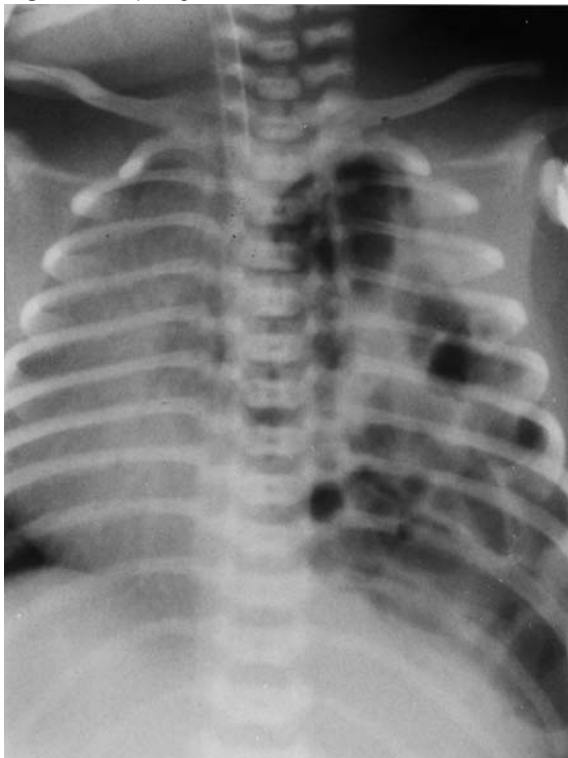### Description of figure 1

“This is a posterior-anterior chest x-ray of GC, born on 06/02/98 and taken on 25/02/01. It is well centred, with no rotation. There is good penetration as indicated by the visibility of the vertebral bodies through the heart shadow. The trachea is patent and deviated to the right, which can be normal. There are no bony abnormalities noted. The heart is normal in size, shape and location, with the apex in the left 5<sup>th</sup> intercostal space in the mid-clavicular line. The cardiac borders are clear and well defined. The chest is not hyperinflated and the costophrenic angles are sharp. Both lung fields are equal in radiolucency with normal vascular markings. The paratracheal lines are not thickened. In the mediastinum, the outlines on the right (for the azygous vein, right hilum, and right atrium) and on the left (for the aortic arch, left hilum, and left ventricle) are clear and well defined.”

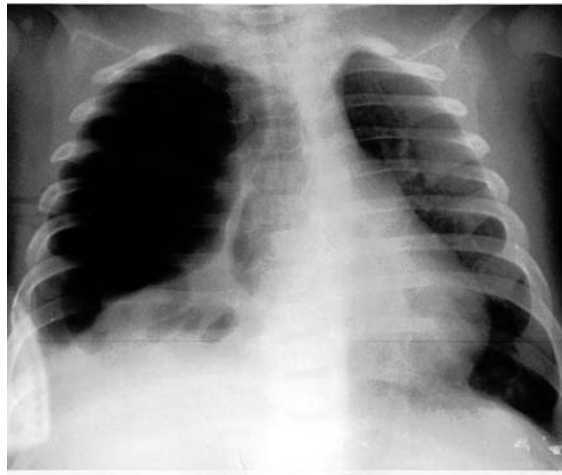
### Description of figure 2

“This is an AP chest x-ray of DJ taken in the neonatal intensive care unit on the day he was born, 14/02/01. This is an unsatisfactory x-ray given that the whole chest was not captured, it is over-penetrated, and the body was rotated to the right. The trachea is deviated to the right and the baby has an endotracheal tube in place. The heart is also displaced to the right by loops of (air filled) bowel seen in the expanded left lung field. Only part of the right lower cardiac border is visible. On the right, the diaphragm is visible and is below the 6<sup>th</sup> anterior rib, indicating hyperinflation. On the left, the diaphragm is not visible. The diagnosis of a diaphragmatic hernia can still be made despite the substandard x-ray.”

**Figure 2:** Diaphragmatic hernia



**Figure 3:** Lower lobe pneumonia with pneumatoceles.



right costophrenic angle. This is distorting the outlines of the azygous vein, right hilum, and right atrium. On the left, the outlines for the aortic arch, left hilum, and left ventricle are clear. This x-ray demonstrates one of the possible complications of staphylococcal pneumonia, a pneumatocele. This is a right lower lobe, not middle lobe pneumonia, since the right cardiac border is still visible.”

### Description of figure 3

“This is a PA chest film taken on 27/01/01 of V.D. born on 04/06/00. Although the patient is centred with both lung apices and costophrenic angles being captured, some of the bony structures are not visible due to poor reproduction. Since the medial ends of the clavicle cannot be seen, the rotation cannot be assessed. The trachea is patent and deviated to the right, as is the heart. The cardiac size and shape are normal but there is a difference in the radiolucency on either side of the vertebral column (darker or less dense on the right). The cardiac borders are well defined on the left but indistinct on the right. The right hemidiaphragm is also indistinguishable with blunting of the costophrenic angle, consistent with a pleural effusion. There is a white region (consolidation), containing discrete dark patches (air) along the right cardiac border, and extending to the

### CONCLUSION

The object of diagnostic imaging is to demonstrate pathological processes beyond the scope of the clinical examination. Chest x-rays may be used to exclude or to diagnose serious chest disease, to provide clear evidence of the patients’ chest condition preoperatively, and also to assess the patient postoperatively for any complications. Most of us approach the reading of an x-ray with some trepidation. Hopefully the outlined systematic approach to the examination of any x-ray will ease this process for many by improving one’s ability to assess and comment upon the relevant findings present on a patient’s x-ray. In applying a systematic approach to ensure complete assessment of a chest x-ray, we hope to illustrate the importance of the simple film in identifying diseases, not only of the lung parenchyma but also of many other systems.

### BIBLIOGRAPHY

♦Come J, *et al.* *Chest X-Ray Made Easy*. Edinburgh Churchill Livingstone, 1997.  
♦Sutton D. *Radiology and Imaging For Medical Students*. Edinburgh Churchill Livingstone, 1998.

♦Sutton D. *A Textbook of Radiology and Imaging – Vol. 1 and 2*. Edinburgh Churchill Livingstone, 1998.  
♦Talley NJ, O’Connor S. *Clinical Examination*. Hong Kong Blackwell Science Ltd, 1996.